

# Chronic Hyperplastic Pulpitis, three Case Reports

Ali Sultan AlRifai<sup>1</sup>, Ramizu Bin Shaari<sup>2</sup>, Mohamad Arif Awang Nawi<sup>3</sup>, Ameera Kamal Khaleel<sup>4</sup>

<sup>1</sup>Dean of College of Dentistry, Ahl Al Bayt University, Karbala, Iraq.

<sup>2,3,4</sup>School of Dental Sciences, Health Campus, Universiti Sains Malaysia, Kubang Kerian, 16150 Kota Bharu, Kelantan, Malaysia

Corresponding author;

Ali Sultan AlRifai

[alrifai@abu.edu.iq](mailto:alrifai@abu.edu.iq)

## Abstract

Chronic hyperplastic pulpitis (Pulp polyp) is associated with molar teeth of children and young adults and is usually characterized by an overgrowth of granulation tissue into a large carious cavity. Here, we report a rare cases of pulp polyps in lower molar of a young and middle-aged males, one is small cherry in color and the other two are grow into carious cavity and extruded in very large size that interfered with occluding of the teeth.

**Keywords:** pulp, polyp, molar, Oral, Pathology.

## 1. Introduction

Pulp polyp is a hyperplastic inflamed dental pulp tissue in an open carious cavity or a fractured tooth due to lack of intra-pulpal pressure which if present in a closed cavity, it may cause pulp necrosis. It is formed as a result of a low-grade inflammation in a vascularized pulpal tissue with a high reactivity and immunity. Pulp polyps can affect both genders and are seen in molar teeth of children and young adults and rare in middle and older aged patients Mohammed [1]. The majority of pulp polyps present without symptoms, but if it becomes subjected to any irritation like mastication, the polyp may become ulcerated and becomes dark red in color. Bleeding may be present depending on the vascularity in the area [1, 2]. A number of management options for teeth with pulp polyps are present, either extraction of the involved tooth, or by restoration, depends mainly on the amount of the sound tooth structure remaining. A delay in the treatment may leads to the spread of the inflammation into the periodontal ligament, increase in dental caries, and fracture of the tooth. Extraction of the permanent molars can lead to malocclusion, aesthetic and some functional problems [3, 4]. Here we report a three cases of pulp polyps in the mandibular permanent molars that grew in a large carious cavities in a young and middle-aged patient.

### Case reports

Three cases of pulp polyps in male patients of 18, 23, and 26 years of age, were seen in the Dental Clinic, Alzahrawi University College, Karbala/ Iraq, associated with a badly carious teeth and surrounded by the remnants of tooth structures. These patients complained only from a mild tooth pain. The intraoral examination showed a polypoid lesion protruding from the carious cavities. One of these pulp polyps appeared small and cherry red in color, and the other two appeared pink, large in size, reaching about

one centimeter in diameter (Figure-1). To differentiate it from the gingival polyp, these pulp polyps were palpated by excavator, and this action revealed the presence of the attachment with the pulp tissue. Because all of these cases were associated with a badly carious teeth, they were treated by extraction.

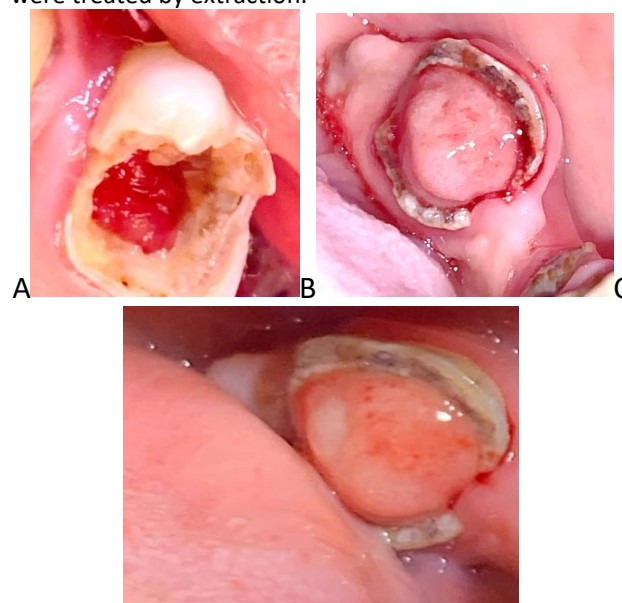


Figure-1: (A) Deep cherry red pulp polyp associated with lower first molar. (B, C) Pink pulp polyps associated with lower second molars.

## 2. Discussion

Pulp polyp is known as chronic hyperplastic pulpitis clinically it appears as proliferative red mass associated mostly with the occlusal surface of a vital molars in individuals with higher immunity and resulting from a long-standing low-grade infection [5]. It is considered as a protective reaction against the inflamed pulp tissue resulting in hyperplastic tissue formation. It occurs in an open cavitated carious or fractured tooth which acts as a pathway for escape of the inflammatory exudate.

Microscopically it shows granulation tissue with abundant blood vessels [6]. A tooth with a pulp polyp presents many difficulties in diagnosis and treatment. Radiographically, the pulpal lesion does not show any periapical changes, but a delay in the treatment may leads to spread of the inflammation into the periodontal ligament through the apical foramen [7]. The treatment plan is either by excision of pulpal growth, crown preparation, endodontic treatment, placement of a post crown, and restoration of the tooth, or by tooth extraction when a minimal amount tooth structure remains [8, 9]. Type I hypersensitivity reactions has been hypothesized to play a significant role in pathogenesis of pulp polyp due to the higher concentration of immunoglobulin, histamine, and Interleukin [10].

### 3. Conclusion

In conclusion, pulpotomy with CEM cement might be a viable

Alternative to tooth extraction for mature molars with Hyperplastic/irreversible pulpitis, and can result in long-term

Tooth retention and improved oral health. CBCT imaging is a

Sensitive and valuable tool to assess the outcome of VPT in

Mature teeth

In conclusion, pulpotomy with CEM cement might be a viable

Alternative to tooth extraction for mature molars with Hyperplastic/irreversible pulpitis, and can result in long-term

Tooth retention and improved oral health. CBCT imaging is a

Sensitive and valuable tool to assess the outcome of VPT in

Mature teeth

In conclusion, pulpotomy with CEM cement might be a viable

Alternative to tooth extraction for mature molars with Hyperplastic/irreversible pulpitis, and can result in long-term

Tooth retention and improved oral health. CBCT imaging is a

Sensitive and valuable tool to assess the outcome of VPT in

Mature teeth

Acknowledgment

The authors thank the patient for giving permission for Publishing this case.

Conflict of Interest: 'None declared'

Acknowledgment

The authors thank the patient for giving permission for Publishing this case.

Conflict of Interest: 'None declared'

Pulp polyp is one of the most commonly seen pulpal pathology in young adults. In this study we highlight the unusual presentation of pulp polyp in a young patient aged 18 years with a cherry red small hyperplastic pulp tissue and two pinks pulp polyps in a middle-aged males. To differentiate it from the gingival polyp, these pulp

polyps were palpated by excavator, and this action revealed the presence of the attachment with the pulp tissue. Because all of these cases were associated with a badly carious teeth, they were treated by extraction.

Conflict of Interest: None declared.

### Reference

1. Mohammed AR, Hassan NAHA, Chalooob AK. Evaluation the effect of pulp polyp on periapical area of primary and permanent dentition: Periapical radiographic Iraqi study. *Mustansiria Dental Journal*. 2017;14(1):118-25.
2. Jabbar NSA, Aldrigui JM, Braga MM, Wanderley MT. Pulp polyp in traumatized primary teeth—a case–control study. *Dental Traumatology*. 2013;29(5):360-4. <https://doi.org/10.1111/edt.12019>
3. Anilkumar K, Lingewaran S, Ari G, Thyagarajan R, Logaranjani A. Management of Chronic Hyperplastic Pulpitis in Mandibular Molars of Middle Aged Adults-A Multidisciplinary Approach. *Journal of Clinical and Diagnostic Research: JCDR*. 2016;10(1):ZD23. <https://doi.org/10.7860%2FJCDR%2F2016%2F15338.7153>
4. Suresh KV, Bajaj N, Nayak AG, Chapi DMK, Patil S, Rani A. Pulp polyp-A periapical lesion: Radiographic observational study. *Journal of Indian Academy of Oral Medicine and Radiology*. 2015;27(1):68. <https://doi.org/10.4103/0972-1363.167085>
5. Attar A, Eslaminejad MB, Tavangar MS, Karamzadeh R, Dehghani-Nazhvani A, Ghahramani Y, Malekmohammadi F, Hosseini SM. Dental pulp polyps contain stem cells comparable to the normal dental pulps. *Journal of clinical and experimental dentistry*. 2014;6(1):e53. <https://doi.org/10.4317%2Fjced.51305>
6. Faryabi J, Adhami S. Unusual presentation of chronic hyperplastic pulpitis: a case report. *Iranian Endodontic Journal*. 2008;2(4):156. Available from: <https://www.ncbi.nlm.nih.gov/pmc/articles/PMC3834634/>
7. Caliřkan M, Oztop F, Caliřkan G. Histological evaluation of teeth with hyperplastic pulpitis caused by trauma or caries. *International endodontic journal*. 2003;36(1):64-70. <https://doi.org/10.1046/j.1365-2591.2003.00590.xs>
8. Abbott P. Examination and diagnosis of pulp, root canal, and periapical/peri-radicular conditions. In: *Ingle's Endodontics 7*. PMPH-USA Limited, 2019. p. 215-66.
9. Asgary S, Verma P, Nosrat A. Treatment outcomes of full pulpotomy as an alternative to tooth extraction in molars with hyperplastic/irreversible pulpitis: a case report. *Iranian Endodontic Journal*. 2017;12(2):261. <https://doi.org/10.22037%2Fiej.2017.51>
10. Sattari M, Haghighi AK, Tamijani HD. The relationship of pulp polyp with the presence and concentration of immunoglobulin E, histamine, interleukin-4 and interleukin-12. *Australian Endodontic Journal*. 2009;35(3):164-8. <https://doi.org/10.1111/j.1747-4477.2009.00160.x>